

SURGICAL OPERCULECTOMY PROCEDURE IN THE TREATMENT OF PERICORONITIS (CASE REPORTS)

Veronica Septina Primasari

Periodontics Departement, Faculty of Denstistry, Universitas Prof. Dr. Moestopo (Beragama), Jakarta

Correspondence: vero_septina@dsn.moestopo.ac.id

ABSTRACT

Background: pericoronitis is an inflammation of the soft tissue around the crown of the erupting or partially impacted mandibular third molar and usually occurs at the age of 20-29 years. This soft tissue is known as the operculum. Pericoronitis is caused by food debris trapped in the operculum and challenging to clean, causing inflammation that can be acute or chronic. Operculectomy is a surgical removal of the operculum and can be performed using a scalpel, laser, and electrocautery. **Case report:** case 1: A 22-year-old female patient complained of frequent pain in the left posterior gingiva, and food was often trapped in the gingiva. Clinical examination showed inflammation in the operculum of an erupted tooth 38. Scaling, the first phase of treatment, is performed to remove plaque and calculus, followed by operculectomy. Case 2: A 20-year-old female patient was referred from the orthodontic department with complaints of difficulty opening her mouth and pain in the left cheek and neck; the patient has been given antibiotics and analgesics. From the clinical examination, tooth 38 erupted with inflammation of the operculum. The patient was given antibiotics and follow-up analgesics to relieve the acute phase, and scaling was done; then, an operculectomy was performed after the patient could open her mouth. **Conclusion:** operculectomy with a scalpel is a procedure that can be performed in treating pericoronitis to remove the operculum; this makes it easier for patients to maintain oral hygiene.

Keywords: operculum, pericoronitis, surgical operculectomy, mandibular third molar

ABSTRAK

Latar belakang: perikoronitis adalah keadaan inflamasi pada jaringan lunak di sekitar mahkota gigi molar ketiga rahang bawah yang sedang erupsi atau impaksi sebagian, dan biasanya terjadi pada usia 20-29 tahun. Jaringan lunak tersebut dikenal sebagai operkulum. Perikoronitis disebabkan adanya sisa makanan yang terjebak di dalam operkulum dan sulit dibersihkan, sehingga menimbulkan inflamasi yang dapat bersifat akut atau kronis. Salah satu penanganan perikoronitis adalah operkulektomi yang merupakan tindakan menghilangkan operkulum. Operkulektomi dapat dilakukan dengan cara menggunakan pisau bedah, laser, dan elektrokauter. **Laporan kasus:** kasus 1: Pasien wanita berusia 22 tahun datang dengan keluhan gusi bagian kiri belakang sering sakit dan terselip makanan. Hasil pemeriksaan klinis terdapat inflamasi pada operkulum gigi 38 dengan gigi sudah erupsi. Skeling yang merupakan fase I perawatan dilakukan untuk menghilangkan plak dan kalkulus, selanjutnya dilakukan tindakan bedah operkulektomi. Kasus 2: Pasien wanita berusia 20 tahun konsul dari bagian ortodontik dengan keluhan sulit membuka mulut, sakit pada pipi dan leher sebelah kiri, pasien sudah diberikan antibiotik dan analgesik. Hasil pemeriksaan klinis gigi 38 sudah erupsi disertai inflamasi pada operkulum. Pasien diberikan antibiotik dan analgesik lanjutan untuk meredakan fase akut dan dilakukan skeling, kemudian tindakan bedah operkulektomi dilakukan setelah pasien dapat membuka mulut maksimal. **Kesimpulan:** operkulektomi dengan pisau bedah merupakan prosedur yang dapat dilakukan pada perawatan perikoronitis untuk menghilangkan operkulum, sehingga memudahkan pasien dalam menjaga kebersihan rongga mulut.

Kata kunci: operkulum, perikoronitis, bedah operkulektomi, molar ketiga mandibula

BACKGROUND

Pericoronitis is an inflammation of the gingiva in relation to the crown of a partially or entirely erupted tooth, most often in the third mandibular area, and can be acute, subacute, or chronic.^{1,2} The

word pericoronitis consists of three words: *peri*, from a Greek word that means “around”, and *corona*, from a Latin word that means “crown”, and *itis* means “inflammation”.³ Pericoronitis is most prevalent in young adults, between age 20-29 years, rarely before

20 or after 40.^{2,3} The soft tissue gingiva, which covers over a partially or entirely erupted tooth, also known as the operculum. Therefore, pericoronitis is also called operculitis.³ The operculum is the area where food debris or plaque may be trapped, allowing bacteria to enter through the opening. This condition will make the standard method of oral hygiene challenging to achieve.^{1,3} The food debris and trapped plaque will lead to inflammation, pain and redness with various degrees of ulceration along its inner surface.^{1,2}

Etiology and risk factors

The common etiology of pericoronitis is food debris and plaque trapped between the crown and the overlying operculum. It is difficult to keep clean, and the operculum is an ideal area for the growth of bacteria.^{1,3} The bacteria are predominantly anaerobic pyogenic bacteria, such as *Peptostreptococcus*, *Porphyromonas gingivalis*, *Prevotella intermedia*, *Fusobacterium nucleatum*, *Bacteroides*, *Capnocytophaga*, *Staphylococcus sp.*, *Propionibacterium* species, and *Actinomyces* species.³⁻⁵ The partially erupted tooth and the degree of mandibular third molar impaction can be a risk factor for pericoronitis. Impacted mandibular third molar can be categorized based on two classifications: (1) Winter's classification (1926): vertical, mesio-oblique, horizontal, disto-angular impactions; (2) Pell and Gregory's classification (1933): availability of space (horizontal plane), relative depth (vertical plane), angulation.⁵ 67% pericoronitis is involved with a vertical impacted tooth, 12% with mesio-angular tooth, 14% disto-angular, and 7% various other positions. Other risk factors are opposing tooth, periodontal pocket, history of pericoronitis, poor oral hygiene, immune system response, and interaction between etiology and risk factors.³⁻⁵ Important factors in the pathogenesis of pericoronitis are emotional or physical stress. Stress has been found to lessen salivary flow, reduce the mechanical or chemical debridement by saliva and normal lubrication of saliva, so that plaque will easily accumulate and cause inflammation.^{3,4}

Clinical features

The severity of pericoronitis can be acute, subacute, or chronic, depending on the factors.^{1,6} Pericoronitis can be diagnosed through clinical examination; therefore, a dentist should ascertain the clinical feature of pericoronitis. Acute pericoronitis is a sudden onset and short, with various degrees of inflammatory involvement of the operculum, may be accompanied by systemic complications, and aggravate by trauma, occlusion, or a foreign body trapped underneath the operculum. The size of the operculum will increase because of the inflammatory fluid and cellular exudate, which can interfere with the closure of the jaws. The clinical features are red,

swollen, suppurating lesion, tender, with slight pain to the ear, throat, and floor of the mouth. This condition makes the patient feel uncomfortable because of pain, bad taste, and inability to close the jaws. Other general finding is swelling of the cheek, lymphadenitis, trismus, and fever. Acute pericoronitis is usually seen in a patient with moderate or poor oral hygiene.¹⁻⁶

Chronic pericoronitis is a recurrent condition of acute pericoronitis, which occur periodically. It is characterized by dull pain, which can last for a few days or months, ulceration and an awful taste. Chronic pericoronitis has usually seen in a patient with excellent or moderate oral hygiene.^{2,3}

In some cases, pericoronitis can be spread into the oropharyngeal area and medially to the base of the tongue, making the patient difficult to swallow. And depending on the severity of the infection, there may be the complicity of the submaxillary, posterior cervical, deep cervical, and retropharyngeal lymph node.¹ Rare condition resulting from acute pericoronitis include abscess formation, cellulitis, and Ludwig's angina.^{1,2}

Management

The management of pericoronitis depends on the severity. In acute conditions with pain and swelling, antibiotics and analgesics are needed, such as amoxicillin 500 mg in combination with metronidazole 400 mg three times a day for five days. Erythromycin 500 mg four times a day for five days can be an option if the patient is allergic to amoxicillin. The area under the operculum needs to be irrigated with warm saline to remove the food debris. In a case of an abscess, drainage is obtained by making an antero-posterior incision with blade No. 15. A local antimicrobial agent such as ozone can be a helpful adjunct in the treatment of pericoronitis. The patient needs to maintain oral hygiene and is instructed to rinse twice a day using 0.12% chlorhexidine or warm salt water.¹⁻³

In conditions after the acute phase subsides, the partially erupted tooth can be treated with the removal of the tooth or the operculum, called operculectomy. Indications for operculectomy are sufficient space for the mandibular third molar, angulation of impacted mandibular third molar, proper alignment and presence of opposing tooth, prosthetic consideration if the mandibular third molar will be used as an abutment, and if the patient refuses to extract the tooth. Operculectomy is a minimally invasive surgery that can be done using a surgical scalpel, lasers, electrosurgery, or caustic agent (such as trichloroacetic acid, ammonia solution, chromic acid, phenol liquefactum). Those methods work well to remove the operculum; however, there are differences in the hemostasis, the width of the cut, healing time, anesthesia required and disagreeable characteristics, such as smoke production, odor of burning flesh, and undesirable taste. The purpose of performing an operculectomy is to leave an area that

is easy to clean and prevent food debris from being trapped.^{3,5,6}

CASE REPORT

Case 1: A 22-year-old female patient complained of frequent pain in the left posterior gingiva; the gingiva sometimes bleeds when brushing teeth, and food was often trapped in the gingiva. Clinical examination showed inflammation in the operculum of an erupted tooth 38. (Figure 1). The patient had good oral hygiene and general health, with laboratory test results: Hb 13.8 g/dL, leukocytes 5.500/mm³, platelets 166.000/mm³, erythrocytes 5.0 million/mm³, ESR 8 mm/hr, BT 1 minute, CT 5 minutes. The radiographic examination showed that tooth 38 fully erupted with vertical angulation and sufficient space. Based on the examination results, the patient was diagnosed with chronic pericoronitis in tooth 38. For the first phase of treatment (initial phase), the patient was given scaling and dental health education. Surgical operculectomy was done in the second phase of treatment (surgical phase). Operculectomy was carried out using blade No. 15 with previous infiltration anesthesia using lidocaine around the operculum 38. Bleeding points were made on the operculum using a pocket marker. Excision started from the lingual, distal, and buccal of tooth 38, ensuring the whole operculum was removed entirely. Scaling and curettage were performed to clean all the plaque and debris. 3% hydrogen peroxide and aquades were used for irrigation. The operative area was sutured with 4-0 silk thread. The patient was given an antibiotic (amoxicillin 500 mg), analgesic (mefenamic acid 500 mg), 0.12% chlorhexidine gluconate, and instructed to keep maintain oral hygiene. One week post-operative, the patient did not complain of any discomfort or pain, and the gingiva around tooth 38

had slight edema. The gingiva was completely healed one month after the operculectomy, and the patient can easily clean tooth 38. (Figure 1).

Case 2: A 20-year-old female patient was referred from the orthodontic department with complaints of difficulty opening her mouth and pain in the left cheek and neck; the patient has been given antibiotics and analgesics. From the clinical examination, tooth 38 had erupted with inflammation of the operculum. Radiographic examination showed tooth 38 has fully erupted with sufficient space and angulation. The patient was diagnosed with acute pericoronitis. The patient was given an antibiotic (amoxicillin 500 mg) and follow-up analgesic (mefenamic acid 500 mg) to relieve the acute phase, and scaling was done. After the acute phase subsided and the patient could open her mouth, surgical operculectomy was planned for the second phase of treatment. The patient had good general health, with laboratory test results: Hb 13.4 g/dL, leukocytes 6.600/mm³, platelets 271.000/mm³, erythrocytes 4.9 million/mm³, ESR 2 mm/hr, BT 1 minute, CT 10 minutes. Infiltration anesthesia was performed with lidocaine around operculum 38. Then bleeding points were made using a pocket marker. Blade No. 15 was used to make an excision on the operculum from lingual, distal and buccal; to ensure that all the operculum was cut. Plaque and debris were cleaned and irrigated using 3% hydrogen peroxide and aquades. Then, the operative area was sutured with 4-0 silk thread. The patient was given antibiotics, analgesics, and 0.12% chlorhexidine gluconate, along with oral hygiene instructions. One week after the operculectomy, the patient felt no complaints, and the gingiva around tooth 38 was slightly edema. Based on the result of one-month post-operative, the gingiva tissue on tooth 38 had healed and was healthy.

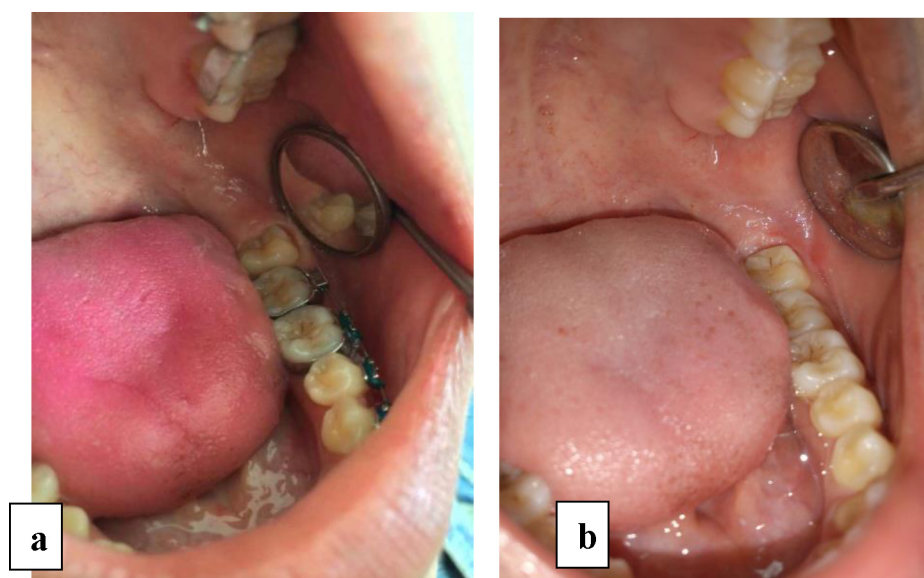


Figure 1. Case 1: (a) Clinical examination before operculectomy. (b) One month after operculectomy.

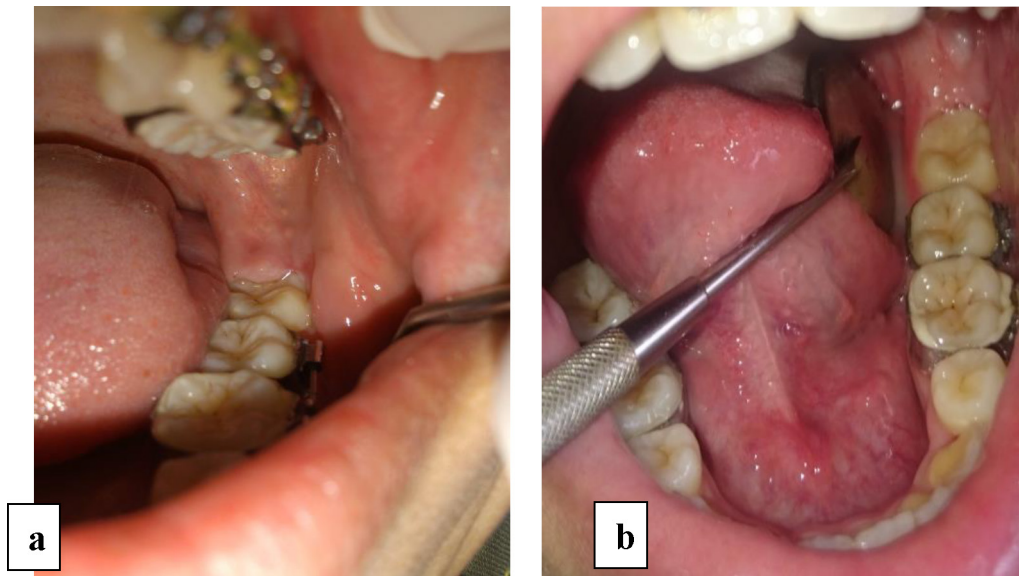


Figure 2. Case 2: (a) Clinical examination before operculectomy. (b) One month after operculectomy.

DISCUSSION

Pericoronitis is an inflammation of the operculum related to erupting tooth, usually the mandibular third molar, which can be acute or chronic.¹⁻⁸ Pericoronitis is most prevalent in young adults, between ages 20-29 years; females are significantly more affected than males^{2,3}, as shown in these two case reports; the patients in cases one and two were females with age 20 years old. Pericoronitis emerge coincide with pre-menstrual and immediate post-menstrual periods. Pregnant women in the second trimester also develop pericoronitis.

Management of pericoronitis depends on the onset and development of the inflammation; it also needs to follow the sequence of the periodontal treatment plan, consisting of the emergency phase, initial phase (phase I), surgical phase (phase II), restorative phase (phase III), and maintenance phase (phase IV).¹ (Figure 3). In case number one, the patient had chronic pericoronitis with frequent pain in the left posterior gingiva, and the gingiva sometimes bleeds when brushing teeth, and food was often trapped in the gingiva. For the treatment plan, surgical operculectomy was carried out in the surgical phase after scaling and dental health education in the initial phase. The patient was not prescribed antibiotics and analgesics in the initial phase because there were no systemic symptoms, and the pericoronitis was not severe.^{2,3}

In case number two, the patient was diagnosed with acute pericoronitis, difficult opening her mouth, and pain in the left cheek and neck; the patient has been given antibiotics and analgesics from the orthodontic department. In the initial phase patient was prescribed antibiotics and analgesics, and then scaling was carried out. After the acute phase subsided, the surgical operculectomy was performed in the surgical phase.³

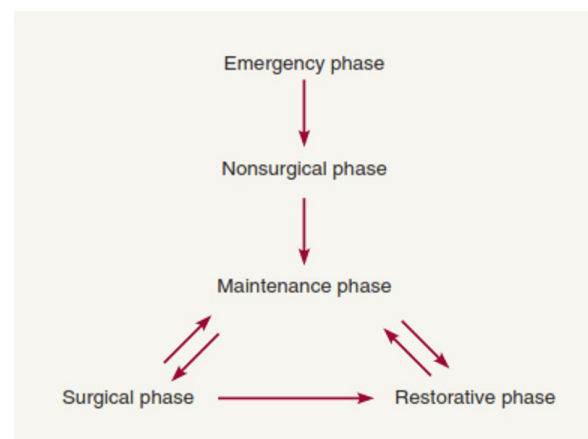


Figure 3. The periodontal sequence of therapy.¹

Operculectomy is a surgical removal of gingival tissue over and around the erupted tooth. The indications for operculectomy are sufficient space for eruption, presence of the opposing tooth, and vertical angulation of the tooth.^{5,6,9} The clinical and radiographic examination of the two cases showed that the patients were indicated for operculectomy. Before performing a surgical operculectomy, it is crucial to evaluate the patient's health condition systemically. Both patients from case one and case two had no systemic disease, and from the routine blood test result were normal.

There are various methods to do operculectomy, such as surgical operculectomy, electrosurgery, laser, or caustic agents.^{3,5,6,10} On electrosurgery uses an electrode that can generate heat. It involves the intentional passage of high-frequency waveforms or currents through the body's tissues to achieve a controllable surgical effect. The advantages of using electrosurgery are coagulation and plugging of micro-diameter blood

vessels, creating an operation area that is free of blood and minimal post-operative edema. Electrosurgery can expedite hemostasis, self-disinfecting tip, reduce edema, and less scarring. Patients with a pacemaker and having poor wound healing, diabetes or bleeding dyscrasias, and a patient who has undergone irradiation were contraindicated for electrosurgery.^{6,10}

Operculectomy also can be done using a diode laser. The most common laser types are diode laser, Er:YAG, CO₂ laser, and Nd:YAG. The diode laser has a compact and portable design. The laser technique has effectively excised gingival tissue, providing adequate hemostasis, less patient discomfort, less chair-side time, reduced bacteremia, reduced healing time and edema. In the use of a laser, there is a reduction in the acute inflammatory response compared to the use of a scalpel, causing the disintegration of cells in the wound tissue without releasing chemical mediators.^{10,11}

Local or caustic agents can be used to cauterize the operculum and control pain. The agents are trichloroacetic acid, ammonia solution, chromic acid, and phenol liquefactum. A small amount of the local agent was placed under the operculum using a cotton pellet. It will lead to rapid pain relief due to chemical cauterization of the nerve endings of pain in the superficial tissues. To avoid injury to adjacent tissues, do so with proper care. The use of these caustic agents is no longer recommended because it is toxic and difficult to control the liquid.³

Surgical operculectomy using the scalpel technique is the gold standard and a traditional technique.¹⁰ In this case reports, operculectomy was performed using blade No. 15, and it was inexpensive and easy to perform. The healing process was gone well, compared to operculectomy using electrosurgery and laser. However, the pain response is more on the surgical operculectomy than electrosurgery and laser.^{6,10} According to Eisenmann *et al.* (1970), there were no differences in the wound healing process at the cellular level under an electron microscope between the scalpel technique and electrosurgery.¹²

The wound healing one month after operculectomy in these two cases showed a good result. There were no inflammation signs on the gingiva, with healthy colour and consistency gingiva around the mandibular third molar. Periodontal tissue wound healing is divided into four phases: hemostasis phase, inflammatory phase, granulation phase, and maturation phase. A fibrin clot attached to the wound area is developed within minutes. In the early phase of inflammation, neutrophils and monocytes are dominant, accumulating around the wound area within hours. Within three days, the late phase of inflammation dominates the healing process as macrophages migrate into the wound, followed by the formation of granulation tissue. Connective tissue may be seen at seven days; however, areas of the fibrin clot

in various stages of maturation may also be observed, depending on wound volume and tissue resources. After the wound is free of bacteria, keratinocytes, fibroblasts, and endothelial cells will try to migrate into the wound. Periodontal tissue maturation will be reached at weeks six to eight, producing a healthy gingiva with coral-pink colour.¹³

The success of operculectomy also depends on the oral hygiene maintenance by the patient. Post-operative instructions are needed: the patient should avoid smoking and eating complex or spicy food, alcohol, and citrus juices following surgery. Toothbrushing may be done carefully in the area around the surgical side. The patient can use ice packs to minimize swelling after extensive surgery. If any problem arises, the patient should call the doctor.¹

CONCLUSION AND RECOMMENDATION

Pericoronitis is an inflammation of the gingiva in relation to the crown of a partially or entirely erupted tooth, commonly occurring in the erupting mandibular third molar area. Management of pericoronitis depends on the onset and development of the inflammation. Surgical operculectomy using a blade is the gold standard, and a traditional technique can still be used to treat excise operculum because it is easy to perform, inexpensive, and has a good healing process. The success of operculectomy treatment also depends on the patient's oral hygiene maintenance.

CONFLICT OF INTEREST

The author declares that there is no conflict of interest in this study.

REFERENCES

1. Newman MG, Takei HH, Klokkevold PR, Carranza FA. Newman and Carranza's Clinical Periodontology. 13th ed. Philadelphia: Elsevier; 2019.
2. Ramalingan B, Ebenezer V, Shanmugapriyan, Ahmed W. Pericoronitis – A review. *European Journal of Molecular and Clinical Medicine*. 2020;7(2):6386-6388. ISSN 2515-8260.
3. Dhonge RP, Zade RM, Gopinath V, Amirisetty R. An Insight into Pericoronitis. *Int J Dent Med Res*. 2015;1(6):172-175.
4. Wehr C, Cruz G, Young S, Fakhouri WD. An Insight into Acute Pericoronitis and the Need for an Evidence-Based Standard of Care. *Dentistry Journal*. 2019;7(88):1-10
5. Parwani S, Kanteshwari IK, Parwani R, Chitnis PJ. Prognosis of Operculectomy Procedure in Vertically Impacted Mandibular Third Molars – A Clinical Evaluation. *International Journal of Clinical Dentistry*. 2012;5(1):25-37.
6. Eleena TN, Chen JLY, Alli MSA, Hosni M. Management of pericoronitis for partial eruption of second permanent molar in a pediatric patient. *Dental Journal (Majalah Kedokteran Gigi)*. 2021;54(4):169-173.

7. Abate A, Cavagnetto D, Fama A, Matarese M, Bellincioni F, Assandri F. Efficacy of Operculectomy in the Treatment of 145 Cases with Unerupted Second Molars: A Retrospective Case-Control Study. *Dentistry Journal*. 2020;8(65):1-8.
8. Galvão EL, da Silveira EM, de Oliveira ES, da Cruz MM, Flecha OD, Falci SGM, *et al*. Association between mandibular third molar position and the occurrence of pericoronitis: A systematic review and meta-analysis. *Archives of Oral Biology*. 2019;107,104486. ISSN 0003-9969. <https://doi.org/10.1016/j.archoralbio.2019.104486>.
9. Ahmed Y, Alaqili S. Pericoronitis of lower third molars teeth: Female: a case report. *Journal of Health Sciences and Nursing*. 2021;6(12):7-11. ISSN 2456-298X.
10. Asok A, Bhandary R, Shetty M, Shetty S. Comparative evaluation of pain response in operculectomy procedures using conventional, electrocautery and laser techniques. *Manipal Journal of Dental Sciences*. 2018;3(1):9-13.
11. Mohi A. Minimally invasive management using laser assisted operculectomy with adjunctive hyaluronic acid: A case report. *Biochem Call Arch*. 2021;21(1):1085-1089.
12. Eisenmann D, Malone WF, Kusek J. Electron microscopic evaluation of electrosurgery. *Oral Surg*. 1970;29:660-665.
13. Polimeni G, Xiropaidis AV, Wikesjo UME. Biology and principles of periodontal wound healing/regeneration. *Periodontology 2000*. 2006;41:30-47.